

# Laser Treatment of Vaginal Atrophy in Post-menopause and Post-gynecological Cancer Patients

Juan F. Bojanini B., Alexandra M. Mejía C.

*Ginestética Laser. Calle 6 sur # 43 A – 200 of 1210. Medellín. Colombia*

## ABSTRACT

Between 4 and 6 of every 10 women undergoing menopause suffer from symptoms related to vaginal atrophy. Dyspareunia, in relation to vaginal dryness, can lead to sexual dysfunction. Vaginal hormone treatment has been regarded as the ideal treatment for vaginal atrophy management. Laser treatment is used to reduce the symptoms generated by vaginal atrophy, and to offer patients an alternative to traditional hormone replacement therapy that minimizes or eliminates the present risks.

The objective of this interventional, prospective study is to analyze data about laser treatment for vaginal atrophy in women with natural menopause in comparison to women with menopause induced by the treatment of cancer of gynecological origin. All patients were treated at the Ginestetica Laser Center. The study's procedures were always ambulatory. Periodic control was made up to 3 months after the laser treatment.

The vaginal atrophy laser treatment results are similar for all treatment groups, independent of whether or not the patient had gynecological cancer. Before treatment, all patients reported to have severe vaginal dryness and severe dyspareunia, and 97.5% of patients avoided having sex as a result of the symptoms. At 3 months post laser treatment, 70% of the patients reported not having vaginal dryness and 30% claimed to have only mild vaginal dryness; 90% of the patients said they did not have dyspareunia and no longer avoided sexual intercourse, while only 10% of the patients remained with mild dyspareunia and rare sex avoidance.

Laser treatment is an excellent alternative for vaginal atrophy symptoms management in menopausal women as well as in post-gynecological cancer patients.

**Key words:** vaginal atrophy, laser treatment, menopause, gynecological cancer, dyspareunia.

*Article: J. LA&HA, Vol. 2014, No.1; pp.65-71.*

*Received: June 16, 2014; Accepted: July 18, 2014*

© Laser and Health Academy. All rights reserved.  
*Printed in Europe. www.laserandhealth.com*

## I. INTRODUCTION

The Women's Health Initiative (WHI) publication has led to many changes. Initially, we suspended the menopausal hormone medication in all patients in an effort to avoid the development of possible breast or colon cancer. Over the following months, patients returned saying that they "preferred to die from cancer than hot flashes". This reaction led gynecologists to rethink certain premises that were then in effect, and as we all know today, the best treatment for menopause symptoms is hormonal replacement therapy.

Vaginal atrophy is the thinning of the vaginal wall that occurs during menopause, which tends to increase 5 or 6 years after the last menstrual period [1,2]. The etiology of vaginal atrophy is the progressive loss of estrogen. In women with a history of gynecological cancer, premature menopause is due to chemotherapy or pelvic irradiation.

Many menopausal women would rather not use hormone replacement therapy (HRT) or local estrogen therapy. Less than half of all women undergoing menopause with vaginal atrophy symptoms are receiving treatment [1]. It is important to note that urogenital atrophy is the only symptom that all menopausal women will experience at some point [3].

It is estimated that between approximately 4 and 6 of every 10 women in menopause suffer from vaginal atrophy-related symptoms, which is the second cause of consultation in menopausal women. The gynecological consultations of nearly 5 out of every 100 women concern dyspareunia (pain with intercourse) in association with vaginal dryness. This percentage is three-to-four times higher in women during menopause, and only increases with age.

We must remember that dyspareunia, in relation to vaginal dryness, can lead to sexual dysfunction. The prevalence of sexual dysfunction attributable to disease or cancer treatment ranges between 35 and 85 percent in men and women [3,4,5].

When comparing different publications in which the sexuality of post-menopausal women was investigated, the percentage results are similar. For

symptoms such as dyspareunia, avoiding intercourse, libido loss, or even discontinuing sex altogether, the difference is that post-menopausal women with a history of gynecological cancer are younger than others [2,4].

In general, oncologists tend to not ask patients with a history of gynecological cancer about their sexuality. They fear not knowing how to handle the concerns of patients. Most of them do not have the tools to manage the symptoms of vaginal atrophy, since those patients should not receive hormones. Vaginal hormone treatment was regarded as the ideal treatment for vaginal atrophy management [6,7], with a Cochrane evidence level I when compared with systemic HRT [1,8,9].

Previous studies have shown that results with laser therapy were even better than those obtained with hormones applied vaginally, in terms of reducing symptoms such as dyspareunia, vaginal dryness, vaginal burning or irritation [6].

Laser treatment can be used in patients who have estrogen contraindicated. In addition, it has almost no contraindications and no known complications. The laser treatment objectives for vaginal atrophy are to reduce the generated symptoms, such as: dryness, itching, and dyspareunia, as well as to offer patients an alternative to traditional HRT that minimizes or eliminates the current risks. Here we can include post-gynecological cancer patients.

Laser therapy for vaginal atrophy arises as an interesting option since it stimulates the connective tissue cellularity, promotes the synthesis of collagen and elastin, strengthens the connective epithelial adhesive system, and favors angiogenesis of the lamina propria and increased epithelial thickness [6].

Laser treatment, especially with the Erbium:YAG laser, produces beneficial changes on the vaginal mucosa that are comparable to those obtained with vaginal hormone treatments.

It is well-known that vaginal tissue must be hydrated to achieve a positive effect from the laser. For this reason, the vagina should be prepared in advance of the laser treatment with either hormones applied locally in the vagina (for those patients who have no contraindication to use estrogen), or by injecting platelet-rich plasma in the vaginal mucosa for those with contraindications. This process has proven to be a very good alternative for good vaginal mucosa hydration.

The aim of the clinical use of platelet rich plasma (PRP) is bio-stimulation, which involves an increase in the concentration of growth factors and the secretion of proteins which are able to maximize the healing of the tissue.

It is a very simple, safe and quick procedure. It is an autologous biological material which carries a minimal risk of immune reactions and transmission of infectious and contagious diseases. The PRP is obtained by centrifuging the patient's blood; its function is directly linked to the release of the growth factors of the platelets themselves [10].

Platelets, whose function is being a natural reservoir for growth factors, include the following: growth factor, platelet-derived (PDGF), epidermal growth factor (EGF), transforming growth factor beta 1 (TGF- $\beta$ 1), vascular endothelial growth factor (VEGF), basic fibroblast growth factor (b-FGF), hepatocyte growth factor (HGF), and Insulin-like growth factor (IGF-I) [11]. Growth factors are recovered and injected directly into the treatment area (vaginal mucosa) to stimulate fibroblasts which produce new collagen and elastin, promoting the formation of new tissue, and resulting in increased smoothness and elasticity of the treated area [12].

The laser treatment consists of 2 sessions with a 3-week interval between them. Patients do not require any particular post-treatment care, and can resume sexual activity within 72 hours. If required, treatment can be repeated without any problem. While the effects obtained with hormone therapy disappear upon the discontinuation of treatment, the effects obtained with the laser treatment are maintained over time.

After we received training in the use of the laser equipment and were convinced of the benefits of this type of treatment in menopausal women, we decided to see the results in patients with vaginal atrophy due to menopause induced by the treatment of gynecological cancer. For that purpose, treatment was applied to patients with a history of gynecological cancer who had symptoms of vaginal atrophy. Our initial results with these patients were not only extraordinary, but also impressive from an emotional point of view.

With such extraordinary results, we decided to design a clinical research study, in which we could compare and document the effects of laser treatment for vaginal atrophy in post-menopausal women with the effects of treatment in women with a history of gynecological cancer.

## II. MATERIALS AND METHODS

The overall goal of this interventional study is to analyze the data about laser treatment for vaginal atrophy in women with natural menopause compared to women with menopause induced by cancer treatment of gynecological origin. The study will collect data on the safety, effectiveness, and satisfaction of patients with this type of treatment as well as the assessments of physicians about the effectiveness and tolerance to the treatment.

Another objective was to prove that the result of the laser treatment for vaginal atrophy is similar when performed either in women with menopause induced by gynecological cancer or in women undergoing natural menopause.

The research protocol was submitted to the Ethics Committee of the Clinical Research Center Foundation, in Medellín, Colombia. After complying with all Committee requirements, the research received approval to be held in Ginestética Laser, which is a comprehensive care center specializing in aesthetic facial, body and vaginal procedures.

### Inclusion criteria:

- Women between 40 and 65 years of age.
- In menopause for at least 2 years prior to entry into the study.
- BMI between 20 and 28.
- To have at least two of the following symptoms of vaginal atrophy: vaginal dryness, pruritus (itching or burning) vaginal pain with intercourse, recurrent symptoms similar to a cystitis-type urinary tract infection.
- Normal recent Pap smear results (last 6 months).
- Negative POP- Q (POP- Q stages 0 or I).
- To have a regular partner and the possibility for an active sex life.
- Willingness to accept the study procedures.
- Willingness to attend Ginestética Laser visits as stipulated by the protocol.
- Accepting that the information provided during the study is to be used in the execution of the study.

For the subgroup of patients with treatment-induced menopause of gynecological cancer origin, in addition to the requirements listed in the previous section:

- Being diagnosed with cancer of gynecological origin (breast, ovary or endometrium) in the past 5 years.
- Receiving adjuvant treatment for their disease, either chemotherapy or pelvic radiotherapy.

### Exclusion criteria:

- Women in menopause who have received hormone replacement therapy either orally, parenterally or

trans-dermally in the past 6 months.

- Women in menopause who, despite meeting the diagnostic time frame (at least 2 years in menopause), do not have symptoms of vaginal atrophy.
- Having a prior vaginal surgery.
- Having a disease based on decompensation: thyroid disease (in this case - compensated medical treatment could be entered), uncontrolled diabetes, or uncontrolled hypertension.
- Sjögren Syndrome
- Smokers
- Women who do not accept the study procedures.

Patients were obtained via the researcher's consultation or were referred either by other physicians or by patients admitted to the same research protocol.

After explaining to patients what the protocol was, we then completed the following together with them: an informed consent, a full gynecological history, a form to confirm that the patient met the inclusion criteria and had no exclusion criteria, a visual scale in which the patient marked her perception of the intensity of her symptoms, and a Modified Sexual Function Index form [13]. Subsequently, the patient was assigned to the group that corresponded to what was stated in the protocol: the patients in the menopausal group (group A) were randomly divided into two sub-groups (A1 and A2), with the A1 sub-group patients receiving vaginal pre-treatment with estriol and the A2 sub-group receiving Platelet Rich Plasma (PRP). All patients with a history of gynecological cancer received PRP (Group B) to prepare the vagina for laser treatment.

The vaginal preparation was carried out for two weeks with hormones for the respective group and then the first session of RenovaLase® (treatment of vaginal atrophy with 2940 nm Erbium YAG laser – Fotona XS Dynamis) was made. Three weeks later, the second laser treatment session was performed. Only local topical anesthesia (2% Lidocaine chlorhydrate gel) was used prior to laser treatment.

In the group of women who received PRP vaginal preparation, the first session of RenovaLase® was carried out two weeks after the PRP application, and the second session was performed three weeks later. The procedure to be performed at each visit and the annexes to be filled were defined and then tabulated in Excel for further analysis.

This study is still in progress, as the follow-up period for each patient lasts one year. We believe such follow-up time is necessary in order to see the full results of laser treatment effectiveness for vaginal atrophy.

### III. RESULTS

40 patients were admitted in the study and were distributed as follows: 20 patients in the post-menopausal group with no history of gynecologic cancer (group A) and 20 menopausal patients with a history of gynecological cancer (group B), all of whom previously had breast cancer. The average age of the patients admitted was similar for the two groups; however, the group of women with a history of gynecological cancer had a higher maximum age and a minimum age lower than the other group. Only one patient in the group of women with a history of gynecological cancer had no children.

Among the symptoms reported on admission to the protocol, all patients reported severe dyspareunia and severe vaginal dryness. All but one patient from group B reported discomfort during intercourse and marked “always” in the question about avoiding sex (see the patients’ data in Table 1).

**Table 1. Patients’ characteristics at enrollment.**

	Normal menopausal Group A (n=20)	Post-cancer Group B (n=20)
Age (years±range)	53.5 (48-57)	52.6 (39-65)
Nulliparous	0	1
<b>Vaginal Atrophy Symptoms:</b>		
Dryness	100% (severe)	100% (severe)
Dyspareunia	100% (severe)	100% (severe)
Avoiding sex	100% (always)	95% (always)

All patients had pre-treatment of vaginal mucosa before laser therapy. Half of the patients in group A received vaginal estriol to prepare the vagina during the 2 weeks prior to treatment. The other half of the patients in group A and all group B patients received platelet rich plasma injected into the vaginal mucosa 2 weeks before laser treatment (see Table 2).

**Table 2. Vaginal preparation before laser treatment.**

	Normal menopausal A1 (n=10)	Normal menopausal A2 (n=10)	Post-cancer B (n=20)
Pre-op therapy	Estriol (Esteine) 2 weeks before laser (0.5 mgr topical; 3x / week)	PRP 2 weeks before laser (injection, 1x)	PRP 2 weeks before laser (injection, 1x)

Vaginal dryness improved in all patients. Severe dryness in 70% of patients improved to non-symptomatic levels and in 30% to mild dryness at 3 months after the laser therapy. Improvement was the best in the A2 subgroup, in which 100% of patients became non-symptomatic at 3 months after the treatment. In the A1 subgroup and B group 40% of patients improved from severe to mild dryness. The results of vaginal dryness improvement are given in Table 3 and presented in Fig. 1.

**Table 3. Vaginal dryness results.**

Patient Group	before	3W after Tx1	3 months after Tx2
A1 (n=10) (normal menopausal, pre-op: estriol)	Severe (100%)	Severe (100%)	No symptoms (60%) Mild (40%)
A2 (n=10) (normal menopausal, pre-op: PRP)	Severe (100%)	Severe (60%) Mild (40%)	No symptoms (100%)
B (n=20) (post cancer, pre-op: PRP)	Severe (100%)	Severe (45%) Moderate (50%) Mild (5%)	No symptoms (60%) Mild (40%)

With regard to dyspareunia, there was also a significant improvement in all patients: 90% of all patients reduced their dyspareunia from severe to none at all and only 10% of patients remained with mild dyspareunia. All patients from group B and subgroup A2 became non-symptomatic, while 40% of patients from subgroup A1 remained with mild dyspareunia. The improvement of dyspareunia is presented in Fig. 2 and in Table 4.

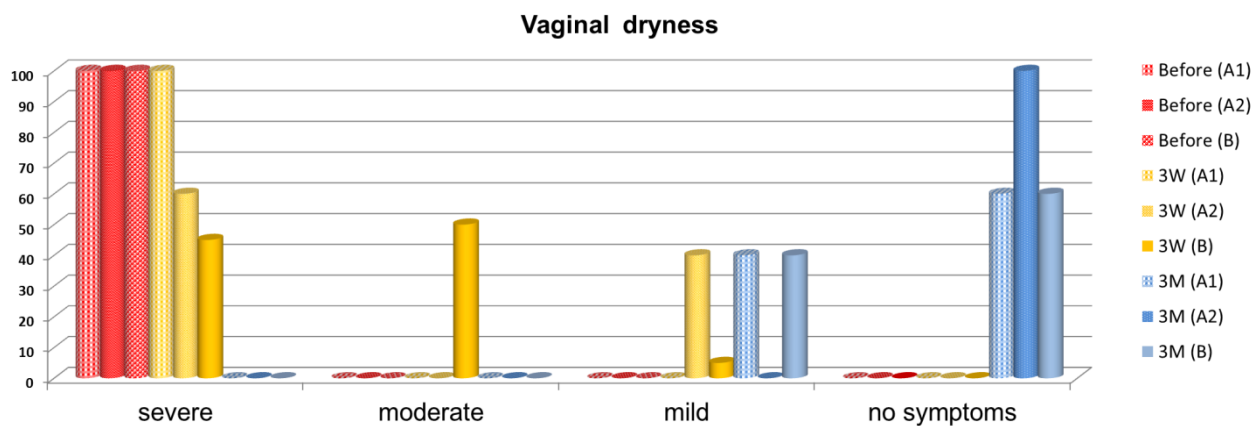


Fig. 1: Improvement of vaginal dryness after the laser therapy. All patients had severe vaginal dryness before the laser therapy (red bars), which had already improved after the first laser session (yellow bars). Vaginal dryness became non-symptomatic for 70% and mild for 30% of the patients at 3 months after the laser therapy (blue bars).

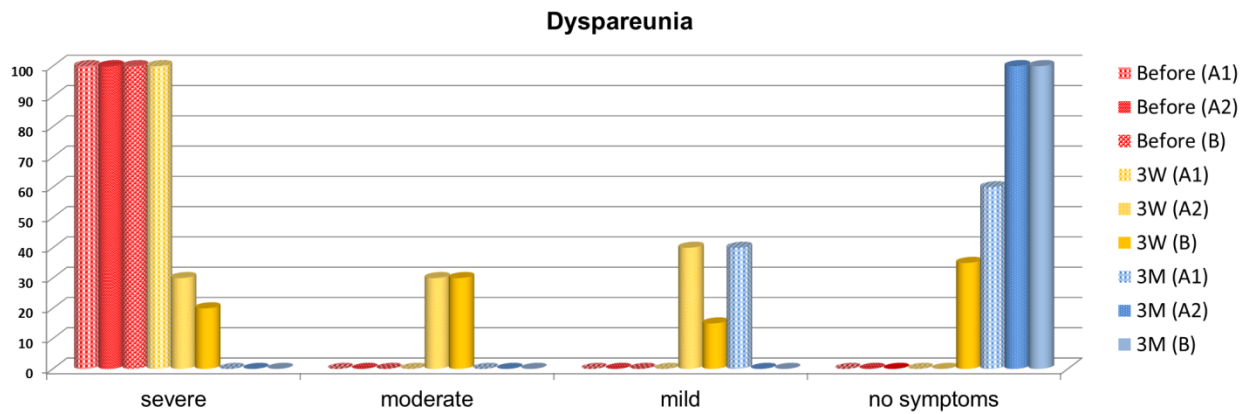


Fig. 2: Improvement of dyspareunia after the laser therapy. All patients had severe dyspareunia before the laser therapy (red bars), which had already improved after the first laser session (yellow bars). Dyspareunia became non-symptomatic for 90% and mild for 10% of the patients at 3 months after the laser therapy (blue bars).

Table 4. Dyspareunia Results.

Patient Group	before	3W after Tx1	3 months after Tx2
<b>A1</b> (n=10) (normal menopausal, pre-op: estriol)	Severe (100%)	Severe (100%)	No symptoms (60%) Mild (40%)
<b>A2</b> (n=10) (normal menopausal, pre-op: PRP)	Severe (100%)	Severe (30%) Moderate (30%) Mild (40%)	No symptoms (100%)
<b>B</b> (n=20) (post cancer, pre-op: PRP)	Severe (100%)	Severe (20%) Moderate (30%) Mild (15%) No Symptoms (35%)	No symptoms (100%)

Table 5. Frequency of patients avoiding sex.

Patient Group	before	3W after Tx1	3 months after Tx2
<b>A1</b> (n=10) (normal menopausal, pre-op: estriol)	Always (100%)	Always (60%) Often (40%)	Never (60%) Rarely (40%)
<b>A2</b> (n=10) (normal menopausal, pre-op: PRP)	Always (100%)	Always (30%) Often (30%) Never (40%)	Never (100%)
<b>B</b> (n=20) (post cancer, pre-op: PRP)	Always (95%) Never (5%)	Always (70%) Often (15%) Rarely (10%) Never (5%)	Never (100%)

The improvement of the patients' sexual life was dramatic. At 3 months after the therapy 90% of all patients reduced sex avoidance from always to never and the remaining 10% from always to rarely. All patients from group B and subgroup A2 became non-symptomatic, while 40% of patients from subgroup A1 improved to rare avoidance of sex. The improvement of the patients' sexual life is presented in Fig. 3 and in Table 5.

At 3 months post treatment, all patients reported satisfaction not only with the treatment, but also with the results (see Table 6). Only one patient (from group B) reported lower satisfaction at the first follow-up (after the first laser session), but she also expressed her full satisfaction at 3 months after the laser therapy.

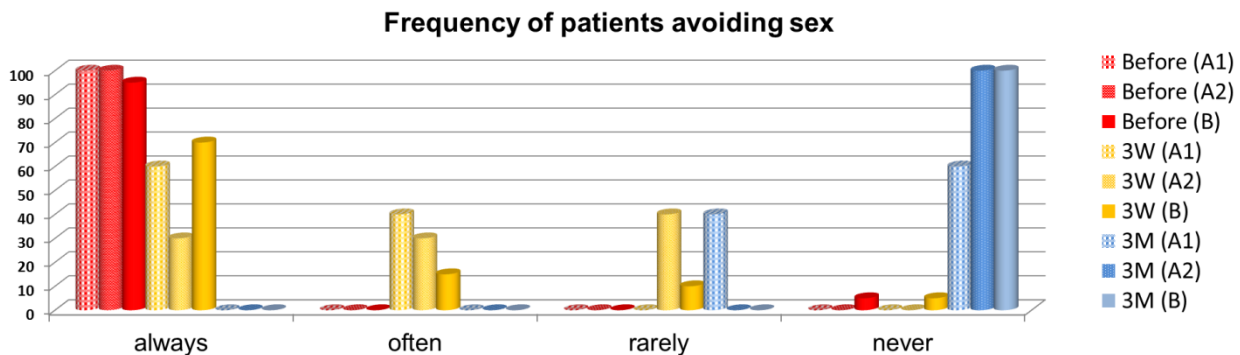


Fig.3. Improvement of the patients' sexual life. All but one patient had always avoided sex before the laser therapy (red bars). The sexual life of the patients had already improved after the first laser session (yellow bars). At 3 months after the laser therapy, 90% of the patients said they no longer (never) avoided sex and 10% of the patients said they rarely avoided sex (blue bars).

**Table 6. Patients satisfaction.**

Patient Group	Satisfaction (3 months after)
A1	100%
A2	100%
B	100%

A few transient adverse effects were reported by a minority of the patients at the first follow-up, like mild pain (2 patients from group B), burning (3 patients from group A2 and 2 patients from group B) and itching (2 patients from group A1). No patient mentioned pain, bleeding, swelling, bruising or infection as a result of the application of the laser for the treatment of vaginal atrophy during this research.

At 3 months follow-up, there were no adverse effects reported (see Table 7).

**Table 7. Adverse effects.**

Patient Group	3W after Tx1	3 months after Tx2
<b>A1</b> (n=10) (normal menopausal, pre-op: estriol)	Vaginal itching (20%)	None
<b>A2</b> (n=10) (normal menopausal, pre-op: PRP)	Vaginal burning (30%)	None
<b>B</b> (n=20) (post cancer, pre-op: PRP)	Vaginal burning (10%) Mild pain (10%)	None

#### IV. DISCUSSION

The position statement from the North American Menopause Society concludes that although the choice of therapy should be guided by clinical experience and patient preference, estrogen can be administered locally to treat the symptoms of vaginal atrophy. Vaginal estrogen therapy should be continued for women as long as the symptoms remain [14].

Studies have indicated that 55% of women using an estrogen-containing transdermal patch and 73% taking oral therapy or percutaneous gel reported relief for vaginal symptoms. In contrast, relief of vaginal symptoms was obtained consistently in 80% to 95% of women using local estrogen therapy [14].

Gynecological cancer and its treatments profoundly affect sexuality [5]. Vaginal hormone therapy may raise systemic estradiol levels, at least in the short term. This reverses the estradiol suppression achieved by aromatase inhibitors in women with breast cancer and is contraindicated [10].

Post-gynecological cancer patients must use anti-estrogenic drug treatments, and thus far it has not been known if this would influence the laser effect [15].

The RenovaLase® Er:YAG procedure can provide better results by avoiding the undesirable complications that are present in more invasive laser treatment alternatives [6].

The results of our study confirm the findings of Gaspar [6] as it relates to the benefits of laser treatment for vaginal atrophy, with results even better than those reported by other authors using hormonal therapy, either vaginal or systemically.

So far, patients with a history of gynecological cancer had no option other than the use of lubricants to reduce dyspareunia as a result of vaginal atrophy. After RenovaLase® treatment, patients were happy. They have been able to have sex again and above all, to enjoy it. Moreover, lubricants were not necessary to have painless penetration.

Considering the results obtained with laser treatment for vaginal atrophy in patients with a history of gynecological cancer, the use of RenovaLase® could represent a major alternative for improving the sexuality and thus the quality of life of such patients.

#### V. CONCLUSIONS

Our clinical validation of Er:YAG laser therapy (RenovaLase®) showed it to be an excellent alternative for vaginal atrophy symptoms management, in menopause women as well as in post-gynecological cancer patients.

This therapy is well tolerated by patients and at 3 months follow-up has shown high efficacy, safety and overall patient satisfaction.

RenovaLase® seems to be equally efficacious regardless of menopause origin (normal or post-cancer induced) as well as of the method of pre-op atrophic mucosa preparation (estriol or PRP).

Further research should clarify the long-term role of laser treatment for vaginal atrophy.

#### REFERENCES

1. Lowry F. Vaginal Atrophy Undertreated, Has Adverse Effect on Relationships. Medscape. Oct 09, 2012.
2. Waknine Y. Sex Improves With Vaginal Atrophy Treatment, Survey Finds. Menopause. Published online June 3, 2013.
3. Ganz P. Treatment of estrogen deficiency symptoms in women surviving breast cancer. Part 4: Urogenital atrophy, Proceedings

- of a conference held at the Board Head Inn Charlottesville, Virginia. *Oncology*: April 1999:551-575.
4. Grau Abalo J, Llantá Abreu MC, Chacón Roge Margarita y Fleites González G. La sexualidad en pacientes con cáncer: algunas consideraciones sobre su evaluación y tratamiento (Sexuality in cancer patients: some comments on the evaluation and treatment). *Rev Cubana Oncol* 1999; 15(1):49-65.
  5. Pallí, C. Sexualidad, comunicación y emociones: estudio situacional con mujeres afectadas de cáncer ginecológico (Sexuality, communication and emotions: Situational study of women suffering from gynecological cancer). *Psicooncología*. January 1, 2010.
  6. Gaspar A, et al. Vaginal Fractional CO2 Laser: A Minimally Invasive Option for Vaginal Rejuvenation. *American Journal of Cosmetic Surgery (AJCS)*. 2011; 28(3):156-165.
  7. Bachmann G, Lobo RA, Gut R, Nachtigall L, Notelovitz M. Efficacy of low-dose estradiol vaginal tablets in the treatment of atrophic vaginitis: a randomized controlled trial. *Obstet Gynecol* 2008; 111: 67-76.
  8. Suckling J, Lethaby A, Kennedy R. Local oestrogen for vaginal atrophy in post menopausal women. *Cochrane Database of Systematic Reviews* 2006, Issue 4.
  9. North American Menopause Society. The role of local vaginal estrogen for treatment of vaginal atrophy in postmenopausal women: 2007 position statement of The North American Menopause Society. *Menopause*. 2007; 14: 357 – 369.
  10. Marques LF, Stessuk T, Camargo IC, Sabeh Junior N, Santos LD, Ribeiro-Paes JT. Platelet-rich plasma (PRP): Methodological aspects and clinical applications. *Platelets*. 2014 Feb 10. [Epub ahead of print].
  11. Middleton KK, Barro V , Muller B , Terada S , Fu FH. Evaluación de los efectos de plasma rico en plaquetas (PRP) terapia implicado en la curación de lesiones de tejidos blandos relacionados con el deporte. *Iowa Orthop J*. 2012; 32: 150-63.
  12. RFA. ¿Qué es el Plasma Rico en Plaquetas? [http://www.clinicarfa.cl/index.php?option=com\\_content&view=article&id=35&Itemid=66](http://www.clinicarfa.cl/index.php?option=com_content&view=article&id=35&Itemid=66). Accessed 24 March 2014.
  13. Blümel JE, Binfa L, Cataldo P, Carrasco A, Izaguirre H, Sarrá S. Índice de función sexual femenina: un test para evaluar la sexualidad de la mujer. *Rev Chil Obst Ginecol* 2004; 69 (2): 118-125.
  14. Simon J, Nachtigall L, Gut R. Et al. Effective treatment of vaginal atrophy with an ultra-low-dose estradiol vaginal tablet. *Obstet Gynecol* 2008; 112: 1053-1060.
  15. Kendall D, Folkner S. Caution: Vaginal estradiol appears to be contraindicated in postmenopausal women on adjuvant aromatase inhibitor. *Annals of oncology* 17:584, January 2006.

The intent of this Laser and Health Academy publication is to facilitate an exchange of information on the views, research results, and clinical experiences within the medical laser community. The contents of this publication are the sole responsibility of the authors and may not in any circumstances be regarded as official product information by medical equipment manufacturers. When in doubt, please check with the manufacturers about whether a specific product or application has been approved or cleared to be marketed and sold in your country.